

VIDEOS IN CLINICAL MEDICINE

Orotracheal Intubation

Christopher Kabrhel, M.D., Todd W. Thomsen, M.D., Gary S. Setnik, M.D.,
and Ron M. Walls, M.D.

INDICATIONS

Orotracheal intubation is indicated in any situation that requires definitive control of the airway. Orotracheal intubation is commonly performed to facilitate control of the airway in a patient undergoing general anesthesia. It is also performed as part of the care of critically ill patients with multisystem disease or injuries. Emergency indications include cardiac or respiratory arrest, failure to protect the airway from aspiration, inadequate oxygenation or ventilation, and existing or anticipated airway obstruction.

CONTRAINDICATIONS

In urgent situations or emergencies, such as when a patient is in cardiac arrest, airway management is of paramount importance, and there are very few contraindications to orotracheal intubation. Orotracheal intubation by direct laryngoscopy is somewhat contraindicated in a patient with partial transection of the trachea, because the procedure can cause complete tracheal transection and loss of the airway. In these cases, surgical airway management may be necessary. Unstable cervical spine injury is not a contraindication, but strict, in-line stabilization of the cervical spine must be maintained during intubation. An assistant should stand at the side of the bed and hold the patient's head, neck, and shoulders in an anatomically neutral position. The anterior portion of the cervical collar is opened or removed to permit the patient's mouth to be fully opened.

When immediate intubation is not required, the difficulty of intubation should first be assessed. This assessment is discussed in detail in the Preparation section, under Sedation and Paralysis.

EQUIPMENT

You will need the following equipment: gloves, a protective face shield, a working suction system, a bag-valve mask attached to an oxygen source, an endotracheal tube with stylet, a 10-ml syringe, an endotracheal-tube holder (cloth tape may be used if a tube holder is not available), an end-tidal carbon dioxide detector, a stethoscope, and laryngoscopes with appropriate blades. The two main types of laryngoscope blades are the Macintosh blade, which is curved, and the Miller blade, which is straight. Each is available in various sizes, and each requires a slightly different technique. The choice of blade depends on the operator's experience and personal preference. A size 3 or 4 Macintosh blade or size 2 or 3 Miller blade can be used in most adult patients.

Endotracheal tubes are sized according to the internal diameter of the tube; 7.0-, 7.5-, or 8.0-mm tubes are appropriate for most adults.¹⁻³ The appropriate tube size for use in children can be determined by adding 16 to the patient's age in years and then dividing by 4 ($[\text{age in years} + 16] \div 4 = \text{tube size}$), by matching the

From the Department of Emergency Medicine, Massachusetts General Hospital, Boston (C.K.); the Department of Emergency Medicine, Mount Auburn Hospital, Cambridge, MA (T.W.T., G.S.S.); the Department of Emergency Medicine, Brigham and Women's Hospital, Boston (R.M.W.); and the Division of Emergency Medicine, Harvard Medical School, Boston (C.K., T.W.T., G.S.S., R.M.W.).

This article (10.1056/NEJMc063574) was last updated on July 21, 2010, at NEJM.org.

N Engl J Med 2007;356:e15.
Copyright © 2007 Massachusetts Medical Society.

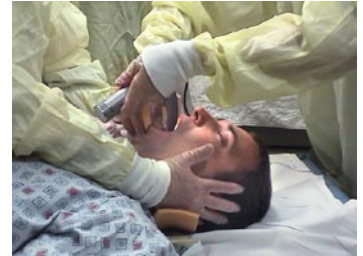

Figure 1. In-line stabilization of the cervical spine

external diameter of the tube to the width of the patient's little fingernail, or by using a system based on the child's height or length (such as the Broslow-Luten resuscitation tape).¹

Tubes can be cuffed or uncuffed. Cuffed tubes are appropriate for adults and older children. Uncuffed tubes are used for younger patients (those requiring a tube smaller than 5.5 mm).^{1,2} After inserting a cuffed tube, you must inflate the balloon on the distal end to create a seal between the tube and the tracheal lumen. This seal will prevent leakage of air and aspiration of gastric contents.

PREPARATION

Before proceeding, be sure that all equipment is readily accessible and functioning, that personnel are properly prepared, and that written informed consent has been obtained from the patient or the patient's health care proxy if the clinical situation permits. Inflate the cuff of the endotracheal tube to check for leaks. Insert the stylet into the endotracheal tube, maintaining the tube's natural curve. Make sure the tip of the stylet does not extend beyond the end of the tube. If necessary, the stylet can be used to reshape the endotracheal tube, as in the "hockey stick" maneuver, to facilitate intubation of an anterior larynx. Ensure that the suction catheter is secure and within easy reach. Obtain intravenous access, and place the patient on a monitor if time and conditions permit. Assign an assistant to watch the monitor during the procedure and to report any changes.

Adjust the height of the bed so that the patient's head is level with the lower portion of your sternum. Unless there are contraindications, move the patient into the "sniffing" position by placing a pillow or folded towel under the patient's occiput. This combination of flexion of the neck and extension of the head improves the alignment of the axes of the oral cavity, pharynx, and larynx, facilitating optimal visualization of the vocal cords.^{1,3} When intubating an infant, you typically do not need to provide additional head support, because the infant's large occiput naturally causes the head to assume the sniffing position.

If the clinical situation allows, preoxygenate the patient with a non-rebreather mask or by having the patient breathe 100% oxygen through a bag-valve mask for at least 3 minutes before intubation.³ Preoxygenation replaces the primarily nitrogenous mixture of ambient air, which constitutes the patient's functional residual capacity, with oxygen. This increases the interval before desaturation in a patient who is hypoventilating or apneic. This preliminary step is essential to minimize the need for positive-pressure ventilation during intubation, thus reducing the risk of aspiration of gastric contents.³

Remove the patient's upper and lower dentures, if present, immediately before laryngoscopy. Re-insert the patient's dentures to improve the mask seal if bag-valve-mask ventilation is required.

If the patient's mental status is diminished or if the patient is pharmacologically sedated, an assistant should apply firm pressure to the cricoid cartilage. This maneuver (the Sellick maneuver) compresses the soft-walled esophagus between the cricoid cartilage and the cervical vertebrae, theoretically preventing passive regurgitation of gastric contents.² If the airway becomes distorted, releasing cricoid pressure may improve visualization of the glottis.

Sedation and Paralysis

In many cases, a neuromuscular-blocking agent and a potent sedative are needed to facilitate intubation. These agents will improve your visualization of the vocal cords and prevent the patient from vomiting and aspirating gastric contents.³ If you plan

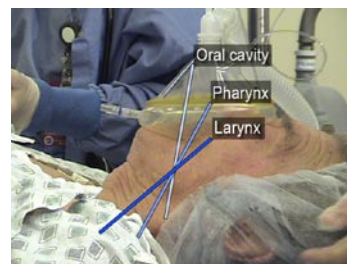

Figure 2. The "sniffing" position

to use such agents, you must assess the difficulty of intubation before proceeding.³ You can generally predict that intubation will be difficult if the patient has a history of difficult intubation, limited neck mobility, a small mandible, pharyngeal structures that are poorly visible through the open mouth with tongue extruded, a limited ability to open his or her mouth, or a laryngeal prominence that is close to the mentum.^{1,3} Anatomical distortion (such as by tumors, trauma, or infection), edema, or obstruction of the airway may also lead to difficult orotracheal intubation. When faced with a potentially difficult intubation, you should make contingency plans, including preparation for an alternative intubation technique, such as using a gum-elastic bougie, a laryngeal mask airway, a fiberoptic intubating bronchoscope, or a surgical technique.

THE PROCEDURE

Position your body so that your eyes are far enough from the patient to facilitate binocular vision. While holding the laryngoscope in your left hand, open the patient's mouth with your right hand. Insert the laryngoscope blade to the right of the patient's tongue. Gradually move the blade to the center of the mouth, pushing the tongue to the left. Slowly advance the blade and locate the epiglottis. Ideal placement of the laryngoscope blade depends on whether a curved or a straight blade is used. If you are using a curved blade, place the tip into the vallecula epiglottica, which is between the base of the tongue and the epiglottis. If you are using a straight blade, place the tip of the blade posterior to the epiglottis.

With the tip of the blade correctly positioned, lift the laryngoscope upward and forward at a 45-degree angle to expose the vocal cords. Direct the force of your lifting action along the axis of the laryngoscope's handle, in the direction of the ceiling, over the patient's feet. Avoid bending your wrist or rocking the blade against the patient's teeth, since this can result in dental or soft-tissue injury (and will not enhance the view of the glottis).

While holding the endotracheal tube in your right hand and maintaining your view of the vocal cords, insert the endotracheal tube into the right side of the patient's mouth. The tube should not obstruct your view of the vocal cords during this critical part of the procedure. Pass the tube through the vocal cords until the balloon disappears into the trachea.

Remove the stylet, and advance the tube until the balloon is 3 to 4 cm beyond the vocal cords. Inflate the endotracheal balloon with air to the minimum pressure required to prevent air leakage during tidal-volume ventilation with a bag. This usually requires less than 10 ml of air. Have an assistant maintain cricoid pressure until you have confirmed that the tube is in the trachea.

Troubleshooting

If you cannot see the vocal cords or epiglottis after positioning the laryngoscope blade, you have probably inserted the blade too far or have not placed the blade precisely in the midline. Withdrawing the blade gradually in the midline will often allow the epiglottis or larynx to drop into view. Manipulating the larynx with your right hand or having an assistant apply firm backward, upward, and rightward pressure (the so-called BURP maneuver) to the larynx can also facilitate visualization of the vocal cords.² An assistant can gently pull the right side of the patient's lip and cheek to enhance visibility of the glottis. If you still cannot see the cords clearly, an assistant should gently release the cricoid pressure, since this compression can sometimes compromise the view. You should always achieve the best possible view of the vocal cords before attempting to insert the endotracheal tube.

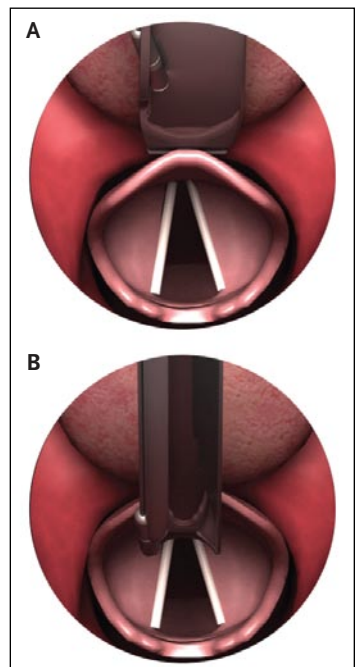


Figure 3. Proper placement of the curved (Panel A) and straight (Panel B) laryngoscope blades

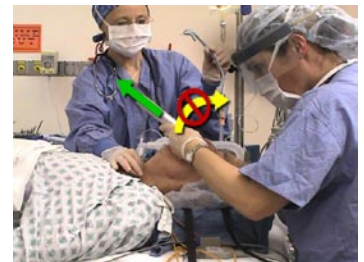

Figure 4. Proper orientation of the lifting action

Confirmation

The end of the endotracheal tube should lie in the mid-trachea, 3 to 7 cm above the carina. A good general rule is to align the 22-cm marking on the tube with the front teeth of an average-sized adult.² For children, you can use the following formula to estimate the proper depth of tube insertion¹: tube depth (in centimeters) = [(child's age in years) ÷ 2] + 12. Place the end-tidal carbon dioxide detector onto the endotracheal tube and attach the ventilation bag, administering a few tidal-volume breaths. Proper tube placement cannot be confirmed solely on the basis of a physical examination or by a finding of fogging of the tube. Other techniques must be used to confirm this most critical aspect of management. Carbon dioxide will be reliably and consistently detected within the first six breaths after orotracheal intubation and with each exhalation thereafter.⁴ In some patients in cardiac arrest, gas exchange does not occur. Thus, carbon dioxide may not be present, even when the tube is in the trachea.⁴ In such cases, you may use a self-inflating bulb (esophageal-detector device) or a fiberoptic endoscope to visualize the tracheal rings.

Perform a secondary assessment to confirm proper esophageal-tube placement by auscultating over the stomach during positive-pressure ventilation. Auscultate both lungs in the midaxillary line to confirm that there is equal, bilateral air movement. If breath sounds are diminished on the left side after intubation, the right main bronchus has probably been intubated. Gradually withdraw the endotracheal tube until symmetrical (i.e., bilateral) breath sounds are auscultated.

Use chest radiography to assess the patient's pulmonary status after intubation and to ensure that the tip of the radio-opaque line embedded in the endotracheal tube is positioned at the level of the mid-trachea and not in either main bronchus. Radiography is not a reliable means of detecting esophageal intubation.

Securing the Tube

Secure the endotracheal tube to the patient's head once you have confirmed that the tube is in the proper position. You should use an endotracheal-tube holder to secure the tube, because this device helps prevent accidental displacement.^{1,2} If such a device is not available, you may use adhesive tape or cloth endotracheal-tube tape. Pharmacologic sedation and hand restraints may be used to prevent the patient from inadvertently removing the tube.

COMPLICATIONS

The most serious complication of endotracheal intubation is unrecognized esophageal intubation, which may lead to hypoxemia, hypercapnia, and death. Laryngoscopy can provoke vomiting and aspiration of gastric contents, causing pneumonitis or pneumonia. Additional complications include bradycardia, laryngospasm, bronchospasm, and apnea owing to pharyngeal stimulation. Trauma to teeth, lips, and vocal cords and exacerbation of cervical spine injuries can also occur.

REFERENCES

1. Lutes M, Hopson LR. Tracheal intubation. In: Roberts JR, Hedges JR, ed. *Clinical procedures in emergency medicine*. 4th ed. Philadelphia: Saunders, 2004:69-99.
2. Schneider RE. Basic airway management. In: Walls RM, ed. *Manual of emergency airway management*. Philadelphia: Lippincott Williams & Wilkins, 2000:43-57.
3. Walls RM. Rapid sequence intubation. In: Walls RM, ed. *Manual of emergency airway management*. Philadelphia: Lippincott Williams & Wilkins, 2000:8-15.
4. *Idem*. Confirmation of endotracheal tube placement. In: Walls RM, ed. *Manual of emergency airway management*. Philadelphia: Lippincott Williams & Wilkins, 2000:27-30.

Copyright © 2007 Massachusetts Medical Society.